

# **Segmental analysis of indocyanine green pharmacokinetics for the reliable diagnosis of functional vascular insufficiency**

Yujung Kang  
Jungsul Lee  
Yuri An  
Jongwook Jeon  
Chulhee Choi

# Segmental analysis of indocyanine green pharmacokinetics for the reliable diagnosis of functional vascular insufficiency

Yujung Kang,<sup>a,b</sup> Jungsul Lee,<sup>a,b</sup> Yuri An,<sup>a,b</sup>  
Jongwook Jeon,<sup>b,c</sup> and Chulhee Choi<sup>a,b,c</sup>

<sup>a</sup>KAIST, Department of Bio and Brain Engineering, Daejeon 305–701, Republic of Korea

<sup>b</sup>KAIST, KI for the BioCentury, Daejeon 305–701, Republic of Korea

<sup>c</sup>KAIST, Graduate School of Medical Science and Engineering, Daejeon 305–701, Republic of Korea

**Abstract.** Accurate and reliable diagnosis of functional insufficiency of peripheral vasculature is essential since Raynaud phenomenon (RP), most common form of peripheral vascular insufficiency, is commonly associated with systemic vascular disorders. We have previously demonstrated that dynamic imaging of near-infrared fluorophore indocyanine green (ICG) can be a noninvasive and sensitive tool to measure tissue perfusion. In the present study, we demonstrated that combined analysis of multiple parameters, especially onset time and modified  $T_{\max}$  which means the time from onset of ICG fluorescence to  $T_{\max}$ , can be used as a reliable diagnostic tool for RP. To validate the method, we performed the conventional thermographic analysis combined with cold challenge and rewarming along with ICG dynamic imaging and segmental analysis. A case-control analysis demonstrated that segmental pattern of ICG dynamics in both hands was significantly different between normal and RP case, suggesting the possibility of clinical application of this novel method for the convenient and reliable diagnosis of RP. © 2011 Society of Photo-Optical Instrumentation Engineers (SPIE). [DOI: 10.1117/1.3556718]

Keywords: peripheral vascular disease; Raynaud phenomenon; optical imaging; indocyanine green.

Paper 10581LRR received Oct. 26, 2010; accepted for publication Jan. 26, 2011; published online Mar. 14, 2011.

Raynaud phenomenon (RP) is an exaggerated vasospastic response of the peripheral tissues such as fingertips to cold exposure or emotional stress due to hypersensitivity of the sympathetic nervous system. Because significant fraction of RP is associated with systemic vascular disorders,<sup>1</sup> it is clinically important to develop a reliable and convenient method for early detection of RP in vascular high-risk groups such as diabetic patients. Although there is no universally accepted objective method for the assessment of RP, infrared thermography in con-

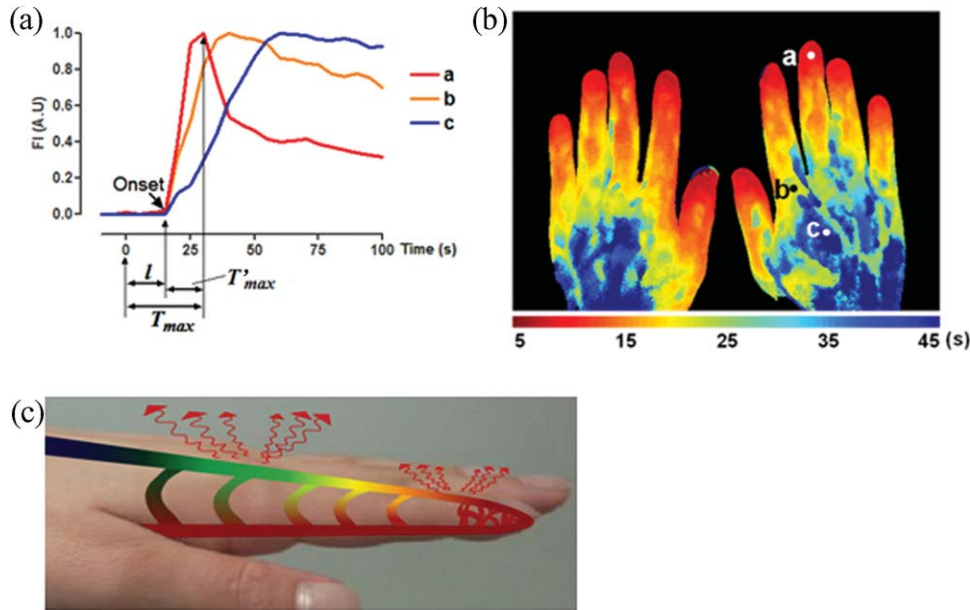
junction with fingertip cold challenge has been used by many groups.<sup>2</sup> Due to high sensitivity to an environmental temperature, rigorous test protocol ensuring thermally controlled environment and careful patient equilibration is needed.<sup>3</sup> However, lack of accuracy and reliability of conventional methods hampers quantitative analysis needed not only for diagnosis but also for proper therapeutic interventions.

We have recently developed a novel optical imaging-based technology for translating indocyanine green (ICG)-time-series images into quantitative measures such as tissue perfusion based on dynamic pattern of ICG, which is mainly dependent on regional tissue perfusion.<sup>4–6</sup> In the present study, we investigated whether segmental analysis of ICG kinetics, especially modified  $T_{\max}$  ( $T'_{\max}$ ) parameter, can be used for the diagnosis of functional peripheral insufficiency such as RP. Because basal skin temperature was significantly lower in RP patients compared to normal,<sup>7</sup> we hypothesized that RP patients would show untypical pattern of the  $T'_{\max}$  in the hands even without cooling stress. To validate the method, we also performed the thermographical monitoring of fingertip after cold challenge. After initial acclimation at 23°C for 20 min in a climate-controlled room, serial thermographic images of the dorsal aspect of both hands were taken for 15 min of rewarming after placing the subject's hands into 15°C water for 1 min. Percentage recovery (PR) [the temperature rise/(initial temperature – temperature immediately after cooling) × 100% at 1, 5, and 9 min after cooling] and rewarming plot were obtained as previously described.<sup>7,8</sup> The study protocol was approved by the institutional review board of Mokdong Medical Center (Seoul, Korea).

For ICG time-series imaging, 96 images (768 × 512 pixels) of the dorsum of both hands were taken at 5 s intervals for 8 min immediately after an intravenous bolus injection of ICG (0.16 mg/kg) using NIR imaging system including two 760 nm LED arrays and a CCD with 830 nm long-pass filter (VasView, Vieworks Corp., Seongnam, Gyeonggi-do, Korea). Regional ICG dynamics obtained from each pixel was analyzed to get value of  $T'_{\max} = T_{\max} - \text{latent time}$ ; while  $T_{\max}$  is the time from ICG injection to maximal fluorescence intensity, and “latent time” is defined as the time from ICG injection to the first onset [Fig. 1(a)]. First onset time was defined as the fastest onset time among the all dynamics from the both hands. ICG dynamics in fingertips showed a steeper slope of increase and decrease of fluorescence signals compared to that of the dorsum [Fig. 1(b)]. To visualize the segmental pattern of ICG dynamics,  $T'_{\max}$  of each pixel in the hand was calculated and translated into a color coded  $T'_{\max}$  map using Visual C++ (version 6.0, Microsoft, USA) [Fig. 1(b)]. Since the arteries are usually seated deep in the dorsum of the hand, most of the ICG fluorescence signals in those areas are from the veins and capillaries; while significant fraction of ICG fluorescence from fingertips represent those of the arteries [Fig. 1(c)]. Thus, typical  $T'_{\max}$  map of a normal subject shows a temporal difference in segmental ICG dynamics as represented in Fig. 1(b) that  $T'_{\max}$  of the fingertips are significantly shorter than that of the dorsum of the hand.

A 40-year-old male who had no history of vascular insufficiency and other vascular risk factors (normal Ankle-Brachial index, Rt. 1.23 and Lt. 1.14), showed PR values, 85.4% and 87.5% at 1 min of the right and left hands, respectively, which

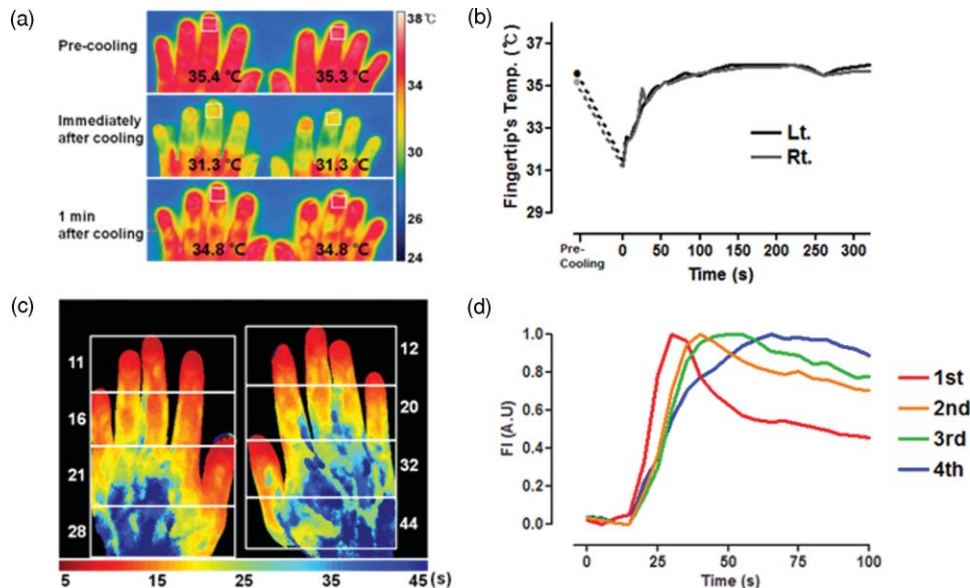
Address all correspondence to: Chulhee Choi, Department of Bio and Brain Engineering, KAIST, 291 Daehak-ro, Yuseong-gu, Daejeon 305-751, Korea. Tel: 82-42-350-4321; Fax: 82-42-350-4380; E-mail: cchoi@kaist.ac.kr; URL: <http://ccbio.kaist.ac.kr>



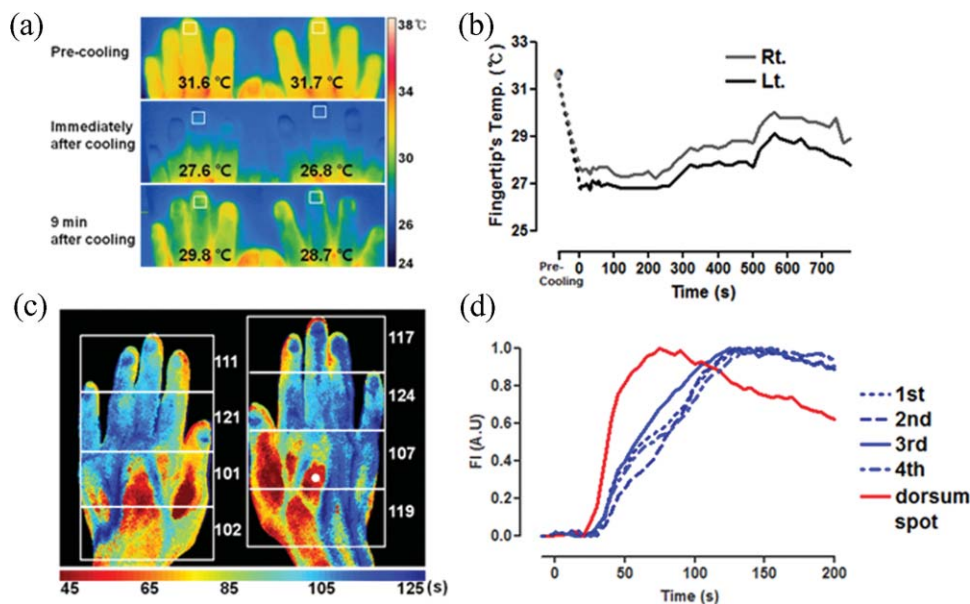
**Fig. 1** (a) ICG dynamics in various points on the dorsum of hand [each point corresponds to the indicated region in (b)].  $l$ , latent time;  $T_{max}$ , time from ICG injection to maximal fluorescence intensity;  $T'_{max}$ , modified  $T_{max}$ . First onset time is indicated by arrow. (b) Color-coded  $T'_{max}$  map constructed based on the time-series ICG images. The ICG images were taken from a 40-year-old healthy male. (c) Schematic reconstruction of ICG circulation through peripheral vasculature in the hand and NIR fluorescence of ICG in the vasculature.

are within normal range [Fig. 2(a)]. The rewarming plot shows that both hand's temperature recovered in 1 min after cooling [Fig. 2(b)]. The pattern of the  $T'_{max}$  map of both hands was consistent with normal peripheral circulation ranging from 5 to 45 s [Fig. 2(c)]. For quantitative analysis of the segmental  $T'_{max}$  pattern, the hand region was evenly divided into four segments from fingertip to carpal region. The average regional  $T'_{max}$  value gradually increased from fingertips to the wrist, and slopes of

the average dynamics of the each region were getting lower as the region is near the carpal region [Figs. 2(c) and 2(d)]. The first onset time was 20 s and fastest  $T'_{max}$  value was 10 s on the fingertip. A 34-year-old woman with subjective symptoms of RP but without previous history of occlusive vascular diseases (normal Ankle-Brachial index, Rt. 1.17 and Lt. 1.16) and vascular risk factors such as hypertension, dislipidemia, and smoking had abnormally low PR value, 2.5% and 2% at 1 min,



**Fig. 2** A 40-year-old male without any symptoms and signs related to vascular insufficiency. (a) Serial thermographic images during cold challenge and rewarming. The number indicates an average temperature in the white box on the last knuckle of the third finger. (b) Dynamics of the average temperatures of both hand's third fingers. (c)  $T'_{max}$  map with a pseudo-color intensity scale. The number beside each region indicates the average  $T'_{max}$  (seconds) of the corresponding segment. (d) Representative ICG dynamics in each segment of right hand. FI (AU) indicates fluorescence intensity (arbitrary unit).



**Fig. 3** A 35-year-old female with RP. (a) Serial thermographic images. (b) Temporal dynamics of the last knuckle's average temperatures of both hand's third fingers during cold challenge and rewarming. (c)  $T'_{max}$  map with a pseudo-color intensity scale. (d) Average ICG dynamics in each region of the right hand. The dorsum spot corresponds with the white dot on the right hand indicated in (c).

15% and 14% at 5 min, and 55% and 39% at 9 min after cooling from right and left hand, respectively [Figs. 3(a) and 3(b)]. As expected,  $T'_{max}$  was significantly delayed (ranging from 45–125 s) and  $T'_{max}$  map showed no segmental difference, which is a hallmark of normal peripheral circulation pattern [Figs. 3(c) and 3(d)]. The first onset time was 25 s, which was consistent with the normal control; however, the  $T'_{max}$  value is markedly delayed up to three times compared to the control. The normal value of first onset time is very critical since it can rule out the possibility of any structural abnormalities hindering the arterial supply to the upper extremities. In patients with severe stenosis in major arteries, the first onset time was significantly delayed compared to the normal control (data not shown).

The present study clearly demonstrates that ICG time-series imaging can be applied to detect abnormal peripheral circulation in patients with RP by segmental analysis of the  $T'_{max}$  along with other parameters. One of the most important advantages of our method is no need for conjugation with cold challenge. Cold challenge and rewarming steps are hard to control and reproduce for quantitative and longitudinal analysis. By obtaining equivalent information without cold challenge and rewarming, it can dramatically increase the reproducibility and reliability of the diagnosis. Even though RP is a reversible episodic spasm triggered by the cold or emotional stress, it is commonly associated with characteristic abnormalities in the function and morphology of the vasculature that can result in irreversible digital ischemia.<sup>3</sup> The present work provides a proof-of-concept evidence for the novel method for diagnosis of functional peripheral insufficiency. This case-control study sufficiently implicated the usefulness of this method for further clinical investigation involving many more patients and much more control. Further large-scale investigation is now being undertaken to confirm the diagnostic value of this proposed method for RP

and other peripheral insufficiency associated with metabolic syndrome.

#### Acknowledgments

This work was supported by the Korea Healthcare Technology R&D Project (A091258), Ministry for Health, Welfare and Family Affairs of the Republic of Korea.

#### References

1. M. Baumhake and M. Bohm, "Recent achievements in the management of Raynaud's phenomenon," *Vasc Health Risk Manag* **6**, 207–214 (2010).
2. J. Foerster, S. Wittstock, S. Fleischer, A. Storch, G. Riemekasten, O. Hochmuth, B. Meffert, H. Meffert, and M. Worm, "Infrared-monitored cold response in the assessment of Raynaud's phenomenon," *Clin. Exp. Dermatol.* **31**(1), 6–12 (2006).
3. L. F. Cherkas, K. Howell, L. Carter, C. M. Black, and A. J. MacGregor, "The use of portable radiometry to assess Raynaud's phenomenon: a practical alternative to thermal imaging," *Rheumatology* **40**(12), 1384–1387 (2001).
4. Y. Kang, M. Choi, J. Lee, G. Y. Koh, K. Kwon, and C. Choi, "Quantitative analysis of peripheral tissue perfusion using spatiotemporal molecular dynamics," *PLoS ONE* **4**(1), e4275 (2009).
5. Y. Kang, J. Lee, K. Kwon, and C. Choi, "Dynamic fluorescence imaging of indocyanine green for reliable and sensitive diagnosis of peripheral vascular insufficiency," *Microvasc. Res.* **80**(3), 552–555 (2010).
6. Y. Kang, J. Lee, K. Kwon, and C. Choi, "Application of novel dynamic optical imaging for evaluation of peripheral tissue perfusion," *Int. J. Cardiol.* **145**(3), 99–101 (2009).
7. D. O'Reilly, L. Taylor, K. el-Hadidy, and M. I. Jayson, "Measurement of cold challenge responses in primary Raynaud's phenomenon and Raynaud's phenomenon associated with systemic sclerosis," *Ann. Rheum. Dis.* **51**(11), 1193–1196 (1992).
8. M. E. Anderson, T. L. Moore, M. Lunt, and A. L. Herrick, "The 'distal-dorsal difference': a thermographic parameter by which to differentiate between primary and secondary Raynaud's phenomenon," *Rheumatology* **46**(3), 533–538 (2007).